POINT-OF-CARE ULTRASONOGRAPHY IN ACUTE CARE: DIAGNOSTIC APPLICATIONS AND CLINICAL IMPACT

A. Jovanovska-Kirovakova[1,2], Z. Kirovakov[2], N. Hinkova[1], K. Tsvetanova[1]

[1]Faculty of Medicine, Medical University – Pleven, Bulgaria
[2]Faculty of Public Health and Health Care, Burgas State University „Prof. Dr. Asen Zlatarov" – Burgas, Bulgaria

ФОКУСИРАНА УЛТРАСОНОГРАФИЯ (POINT-OF-CARE ULTRASONOGRAPHY) ПРИ ОСТРИ СЪСТОЯНИЯ: ДИАГНОСТИЧНИ ПРИЛОЖЕНИЯ И КЛИНИЧНО ЗНАЧЕНИЕ

А. Йовановска-Кировакова[1,2], З. Кироваков[2], Н. Хинкова[1], К. Цветанова[1]

[1]Факултет по медицина, Медицински университет – Плевен
[2]Факултет по обществено здраве и здравни грижи, Бургаски държавен университет „Проф. д-р Асен Златаров" – Бургас

Abstract:

Point-of-care ultrasonography (POCUS) offers a focused, real-time approach to bedside imaging that can complement conventional clinical assessment by directly visualizing selected cardiovascular, pulmonary, vascular, and abdominal physiological abnormalities. POCUS differs from conventional ultrasonography through its question-directed nature, immediate clinician interpretation, integration with the clinical encounter, and capacity for repeated assessment as maternal physiology changes. This narrative review examines the role of POCUS in acute obstetric care from a mechanistic and operational perspective, with particular emphasis on maternal physiological phenotyping, clinical decision-making, and maternal outcomes. Current evidence supports its diagnostic and physiological utility more strongly than its direct effect on maternal outcomes. Future research should therefore move beyond demonstrating that POCUS can detect pathology toward determining whether standardized, serial, and outcome-directed POCUS-guided care can reduce severe maternal morbidity, improve resource utilization, and ultimately contribute to reductions in maternal mortality.

Key words:

point-of-care ultrasonography, acute obstetric care, maternal medicine, physiological phenotyping, hemodynamic assessment, maternal outcomes

Address for correspondence:

Zlatko Kirovakov, MD, PhD, e-mail: kirovakov@yahoo.com

Резюме:

Ултрасонографията на мястото на грижата (point-of-care ultrasonography – POCUS) предлага фокусиран, насочен към конкретен клиничен въпрос и извършван в реално време подход към ултразвуковата диагностика край леглото на пациента, който допълва конвенционалната клинична оценка чрез директна визуализация на определени сърдечносъдови, белодробни, съдови и абдоминални физиологични отклонения. POCUS се различава от конвенционалната ултрасонография със своя въпрос-ориентиран характер, незабавната интерпретация от клинициста, интегрирането му в непосредствения клиничен преглед и възможността за повторна оценка при настъпване на промени в майчината физиология. В настоящия наративен обзор се разглежда ролята на POCUS в острата акушерска помощ от механистична и оперативна гледна точка, с особен акцент върху физиологичното фенотипизиране на майката, клиничното вземане на решения и майчините клинични резултати. Настоящите доказателства подкрепят по-силно диагностичната и физиологичната полезност на метода, отколкото директния му ефект върху майчините клинични резултати. Поради това бъдещите изследвания трябва да надхвърлят демонстрирането на способността на POCUS да открива патологични състояния и да определят дали стандартизираното, серийно и ориентирано към клиничните резултати приложение на POCUS може да намали тежката майчина заболеваемост, да оптимизира използването на здравните ресурси и в крайна сметка да допринесе за намаляване на майчината смъртност.

Ключови думи:	ултрасонография на място на грижата, остра акушерска помощ, майчина медицина, физиологично фенотипиране, хемодинамична оценка, майчини клинични резултати
Адрес за кореспонденция:	*Д-р Златко Кироваков, дм, e-mail: kirovakov@yahoo.com*

Introduction

The large-scale integration of Point-of-Care Ultrasonography (POCUS) in acute care has significantly revolutionized the incorporation of ultrasound into clinical assessment. POCUS has emerged as a rapid and noninvasive bedside tool for hemodynamic assessment in critical care and emergency medicine [1, 2]. Lung ultrasound enables semiquantitative assessment of extravascular lung water and early detection of pulmonary congestion [3, 4], and focused cardiac ultrasound can provide real-time evaluation of cardiac structure, filling status, and ventricular performance [5], thereby offering comprehensive assessment of acute conditions such as maternal cardiovascular adaptation during the immediate postpartum period. POCUS places ultrasonographic visualization directly within the clinical process, which allows for the acquisition and interpretation of focused images for immediate diagnostic and management assessment [6, 7]. Presently, POCUS has become increasingly integrated into emergency and critical-care practice, with applications extending across cardiac, thoracic, vascular, abdominal, obstetric, and procedural domains even with the uneven and limited translation of its mechanistic and operational experience into acute care, more so, maternal-related pathways. Existing work provides a stronger foundation for several specific physiological and diagnostic applications and not a comprehensive, outcome-oriented maternal POCUS system. The resulting evidence gap is therefore not simply whether an ultrasound abnormality can be identified, but the demonstration of a sonographic or physiological abnormality and recognition of its contribution to acute maternal outcomes. Against this background, this narrative review examines point-of-care ultrasonography in acute obstetric care from a mechanistic, physiological, and operational perspective, with particular emphasis on maternal outcomes with a specific focus on the pathway linking maternal pathophysiology, POCUS-derived physiological phenotyping, clinical interpretation, treatment modification, physiological reassessment, and maternal outcomes.

Clinical Significance and Operational Integration of Point-of-Care Ultrasonography into Acute Obstetric Care

The conceptual significance of POCUS depends on its capability to identify anatomical lesions and as a means of assessment of dynamic physiological states. Over the years, traditional imaging techniques in medicine have often been framed around the identification and characterization of structural abnormalities as opposed to POCUS, which retains this anatomical capability, while allowing the clinician to assess physiological processes at the bedside, including ventricular performance, cardiac chamber relationships, pulmonary interstitial fluid, pleural abnormalities, venous thrombosis, intravascular filling-related features, and selected abdominal or pelvic findings [8-10]. In acute care practice, analytical results and insights derived from POCUS can be assembled into a physiological profile for assessment of the state of the patient rather than mere identification of existence of abnormality [11]. During pregnancy, POCUS is effectively relevant in identification and assessment of obstetric complications, most of which manifest initially through nonspecific physiological disturbances [12, 13]. In this regard, POCUS produces a comprehensive symptom-based assessment that generates a narrow differential diagnosis with an immediate establishment of the dominant psychological pathway through a detailed assessment of the underlying psychological state [14]. At the bedside, in obstetric and gynecologic care, POCUS is recognized as a standard diagnostic practice and can be used for evaluation of intrauterine pregnancy through assessment of maternal characteristics such as fetal vitality, multiple pregnancy, and gestational age which can be used to rule out red flags such as ectopic pregnancy, fetal complications, or stillbirth [15-17]. The distinction in the significance of POCUS between anatomical visualization and physiological phenotyping is particularly relevant in obstetrics due to the continuous physiological changes and adaptation of pregnant women which directly influences the pathology of

maternal cardiovascular and respiratory systems [18, 19]. Apart from its technical capabilities, POCUS has been reported by a wide range of recent studies to be more cost-effective and time-efficient as compared to the conventional ultrasonography in obtaining the required physiological data which can reduce the length of hospital stay [20, 21]. Hypothetically, the clinical significance of POCUS is not limited to one specialty, protocol, or organ system, but it rather provides real-time diagnostic and monitoring information and can be used to enhance the safety of standard ultrasound-guided procedures.

While the effectiveness and clinical significance of POCUS have been firmly established, its utility is extensively reliant on its operational integration into care. Technically, the operation of POCUS entails a sequential but iterative process involving clinical presentation and assessment, acquisition of a targeted POCUS examination, interpretation of the resulting anatomical and physiological information, integration with conventional clinical data, and subsequent management or escalation [22]. Ultrasound imaging relies on sound waves to generate real-time images, with frequency playing a critical role in determining both the image resolution and depth of penetration [23]. Higher-frequency probes provide better image resolution but have limited depth, making them ideal for superficial structures, while lower-frequency probes penetrate deeper at the expense of spatial resolution [24, 25]. This operational model is particularly relevant to acute obstetric care because maternal deterioration may involve several interacting physiological systems simultaneously. POCUS can facilitate this integrated assessment by allowing multiple physiological domains to be interrogated sequentially at the bedside, rather than treating each possibility as an isolated diagnostic problem [26]. To this end, the examination of a POCUS result requires an interpretation within a dynamic physiological reference frame rather than against a static anatomical model to identify the mechanisms responsible for the observed clinical presentation [27]. As such, the clinical value of maternal POCUS depends not only on the visualized results, but also on the interpretation of the findings within the context of the alteration of cardiovascular, respiratory and vascular physiological pathways. Maternal POCUS can, therefore, be understood as physiology-informed bedside imaging where the sonographic examination and the maternal physiological context are inseparable.

Point-of-Care Ultrasonography Application in Maternal Physiological Phenotyping

The principal clinical value of POCUS in acute obstetric care extends beyond the identification of discrete anatomical abnormalities. Its greater potential lies in its capacity to convert routinely observed clinical signs into a more directly observable representation of maternal physiology [28]. The technique introduces an extra layer of physiological assessment that allows selected components of various processes to be visualized at the bedside [29, 30]. For example, various components of POCUS such as focused cardiac ultrasonography can provide information regarding ventricular systolic performance, chamber dimensions and ventricular interaction, while sonographic manifestations of interstitial fluid accumulation, pulmonary edema, pleural effusion, pneumothorax, or focal pulmonary disease can be easily identified by lung sonography. The findings from POCUS can be interpreted as a collection of independent ultrasound findings, which can be integrated to construct a maternal physiological phenotype [31]. In particular, pulmonary B-lines can provide insights on increased interstitial fluid, but their interpretation becomes substantially more informative when considered alongside left ventricular function, chamber dimensions, pleural findings, blood pressure, oxygenation, and the clinical context [32]. On a similar note, right ventricular enlargement acquires different clinical significance when accompanied by evidence of deep-vein thrombosis, hypoxemia, tachycardia, or other features suggestive of acute pulmonary vascular loading [33, 34]. Physiological phenotyping therefore requires pattern integration, but not isolated image recognition.

The distinction between physiological phenotyping and disease labelling is a central diagnostic question that needs to be answered when using POCUS in acute obstetric care. Typically, physiology-oriented POCUS identifies the physiological pathway through which disease is affecting the patient, which may subsequently narrow the differential diagnosis and, importantly, influence the urgency and direction of management [35, 36]. For example, in relation to hypertensive pregnancy disorders, POCUS can contribute to determining whether the maternal circulation is characterized predominantly by reduced filling, impaired myocardial performance, right-sided pressure overload, or another hemodynamic state [37, 38]. In addition, there are other conditions such as hemorrhage where POCUS can support recognition of a hypovolemic phenotype [39], in sepsis where it may identify a mixed state involving vasodilation,

altered filling, and myocardial dysfunction [40], and acute cardiopulmonary disease where it may reveal a combination of ventricular dysfunction and pulmonary abnormalities [41]. Further, it is worth acknowledging the potential of multi-organ POCUS integrated maternal assessment in providing information about the cardiovascular, respiratory, volume-related, thromboembolic, and hemorrhagic components of acute maternal illness. Within this context, the conceptual advantage is that maternal deterioration can be represented not as a single abnormal measurement or isolated ultrasound finding, but as a multisystem physiological state, allowing the technical capabilities of POCUS to be relevant. This integrated approach is particularly relevant to shock, where the same blood-pressure abnormality may arise through markedly different mechanisms; severe preeclampsia, where vascular dysfunction, altered cardiac loading, and pulmonary fluid accumulation may coexist; postpartum deterioration, where rapid changes in circulatory loading can interact with cardiomyopathy, pulmonary edema, hemorrhage, or thromboembolism; sepsis, where vasoplegia, capillary leak, myocardial dysfunction, and pulmonary complications may occur simultaneously; and suspected pulmonary embolism, where venous thrombosis and right ventricular consequences can provide complementary physiological information. Table 1 shows the principle physiological information provided by the different POCUS domains and the respective potential question.

Point-of-Care Ultrasonography Diagnostic Applications and Clinical Outcomes

The diagnostic applications of POCUS entail a typical sequential process that provides bedside information, which can change the possible interventions and alter the trajectory of acute maternal illness. Critically, the clinical consequences of the related diagnostic applications are observed when POCUS modifies diagnostic reasoning, treatment selection, escalation of care, or subsequent reassessment, apart from the accurate identification of underlying pathophysiological pathways that might contribute to a particular condition [42]. However, it is important to note that POCUS diagnostic accuracy should not be equated with a clinical impact, and the related usefulness has greatest potential value when diagnostic information is obtained sufficiently early to influence a time-sensitive clinical decision, more so, in acute obstetric illness, where there can be a rapid progression from physiological disturbance to organ dysfunction. An applicable mechanism through which POCUS may influence maternal outcomes is reduction in the time between clinical deterioration and acquisition of actionable physiological information by compressing the different sequential steps of the conventional diagnostic pathways to provide an early physiological assessment while definitive diagnostic pathways are being initiated or considered [43]. For instance, the clinical team may perform bedside cardiopulmonary POCUS on a woman who has acute dyspnea while also determining whether definitive imaging is necessary. While evidence of deep vein thrombosis or right ventricular pressure overload may enhance the urgency of additional testing for thromboembolic disease, finding evidence of a strong pulmonary congestion phenotype may have an immediate impact on fluid and respiratory management interventions. Therefore, the potential result improvement stems from early access to clinically relevant information rather than just quicker imaging. Instead of making assumptions, prospective evaluation is needed to see whether this results in quantifiable decreases in deterioration, ICU hospitalization, or other maternal outcomes.

Table 1. Point-of-Care Ultrasonography Domain and the Related Physiological Information.

POCUS domain	Principal physiological information	Potential clinical question
Cardiac POCUS	Ventricular function, chamber dimensions, cardiac loading	Is myocardial dysfunction or abnormal loading contributing to deterioration?
Lung POCUS	Interstitial fluid, pulmonary edema, pleural and focal lung abnormalities	Is respiratory deterioration related to pulmonary congestion or another pulmonary process?
Venous POCUS	DVT and selected indicators of venous/right-sided congestion	Is thromboembolic disease or venous congestion contributing to the presentation?
Abdominal POCUS	Free fluid and selected intra-abdominal abnormalities	Could hemorrhage or another abdominal process explain deterioration?
Integrated POCUS	Combined cardiac, pulmonary, venous and abdominal phenotype	What multisystem physiological state best explains the patient‘s deterioration?

Acronyms: DVT – deep vein thrombosis; POCUS – Point-of-Care Ultrasonography

The next step in the process is to determine whether the POCUS results effectively influence treatment. The idea of physiological phenotyping becomes especially crucial in this context since acute maternal illnesses that seem clinically identical might need essentially distinct treatments. In severe hypertensive disease, maternal dyspnea may arise in the setting of increased vascular resistance, altered ventricular loading, endothelial dysfunction, and pulmonary fluid accumulation [44, 45]. When interpreted in conjunction with cardiac findings and the clinical context, a POCUS showing a pulmonary congestion phenotype can identify a patient in whom indiscriminate fluid administration may be harmful and in whom appropriate fluid restriction, diuretic therapy when indicated, antihypertensive treatment, respiratory support, or higher-level monitoring may be necessary.

Preventing an incorrect therapy rather than just facilitating treatment is a significant but occasionally disregarded mechanism of POCUS advantage [46], and is especially important in cases of maternal critical illness, where a number of significant obstetric emergencies may present with similar clinical symptoms, yet call for different approaches to treatment. This creates an important conceptual distinction between diagnostic benefit and decision-safety benefit, and POCUS may improve care not only by finding a condition that would otherwise have been missed, but also by reducing uncertainty around competing treatment strategies. However, this potential requires a close and careful evaluation, since a POCUS examination can itself produce misleading reassurance if image acquisition is technically inadequate, interpretation is incorrect, or an abnormality outside the scope of the examination is overlooked. As such, the prevention of inappropriate treatment depends on competent acquisition, appropriate interpretation, and integration with the broader clinical picture.

The diagnostic applications of POCUS entail a sequential and iterative process that provides bedside information capable of influencing diagnostic reasoning, treatment selection, escalation of care, and subsequent reassessment. In acute maternal illness, the clinical value of POCUS is greatest when physiological information is obtained early enough to influence time-sensitive clinical decisions. Rather than being used as an isolated imaging examination, POCUS should therefore be integrated with the clinical presentation and conventional clinical assessment to identify the dominant physiological pathway underlying maternal deterioration.

As illustrated in Figure 1, the diagnostic role of POCUS extends beyond the identification of individual ultrasound abnormalities. Findings from cardiac, lung, venous, and abdominal examinations should be interpreted together with vital signs, oxygenation, laboratory findings, and the clinical context to establish an overall maternal physiological phenotype. This integrated approach may help distinguish between hypovolemic or hemorrhagic, pulmonary congestion, cardiac dysfunction, thromboembolic, and mixed physiological states, thereby narrowing the differential diagnosis and supporting more appropriate clinical decisions.

Implementation, Training, Safety and Evidence Limitations

Critical factors that influence the clinical effectiveness of maternal POCUS are the conditions under which it is performed, interpreted, and incorporated into clinical decision-making. It is important to understand that POCUS is highly dependent on the interaction between the operator, the ultrasound device, the clinical question, and the patient's physiological state and, as a result, implementation should be understood as a clinical system rather than a technology acquisition exercise. First, in relation to the operator, the whole process involved in POCUS requires appropriate probe selection, positioning, orientation, depth, gain, optimization, and recognition of relevant anatomical structures [47], all of which require clinical competence and experience. At the same time, the interpretation requires the operator to distinguish meaningful physiological abnormalities from normal variants, technical artifacts, and findings that are non-specific in isolation, making it possible for the same examination to produce different levels of diagnostic information depending on operator competence and clinical experience. The competency of the operator requires clinical indication, technical acquisition, image interpretation, and clinical integration, and related training procedures should be linked to specific clinical applications and should progress from supervised image acquisition toward independent interpretation and appropriate clinical decision-making. In addition, quality assurance is particularly important during training programs, and regular review can identify systematic weaknesses before they become embedded in clinical practice [48]. Multidisciplinary integration is equally important, and maternal POCUS programs should operate with collaboration among obstetricians, maternal-fetal medicine specialists, anesthesiologists, emergency physicians, intensivists, radiologists, cardiologists, and appropriately trained sonographers [49, 50]. The appropriate governance model is therefore not one in which POCUS competes with radiology, cardiology, or formal ultrasonography but rather maintaining the balance between speed and diagnostic rigor, accessibility and competency, and bedside autonomy and multidisciplinary oversight.

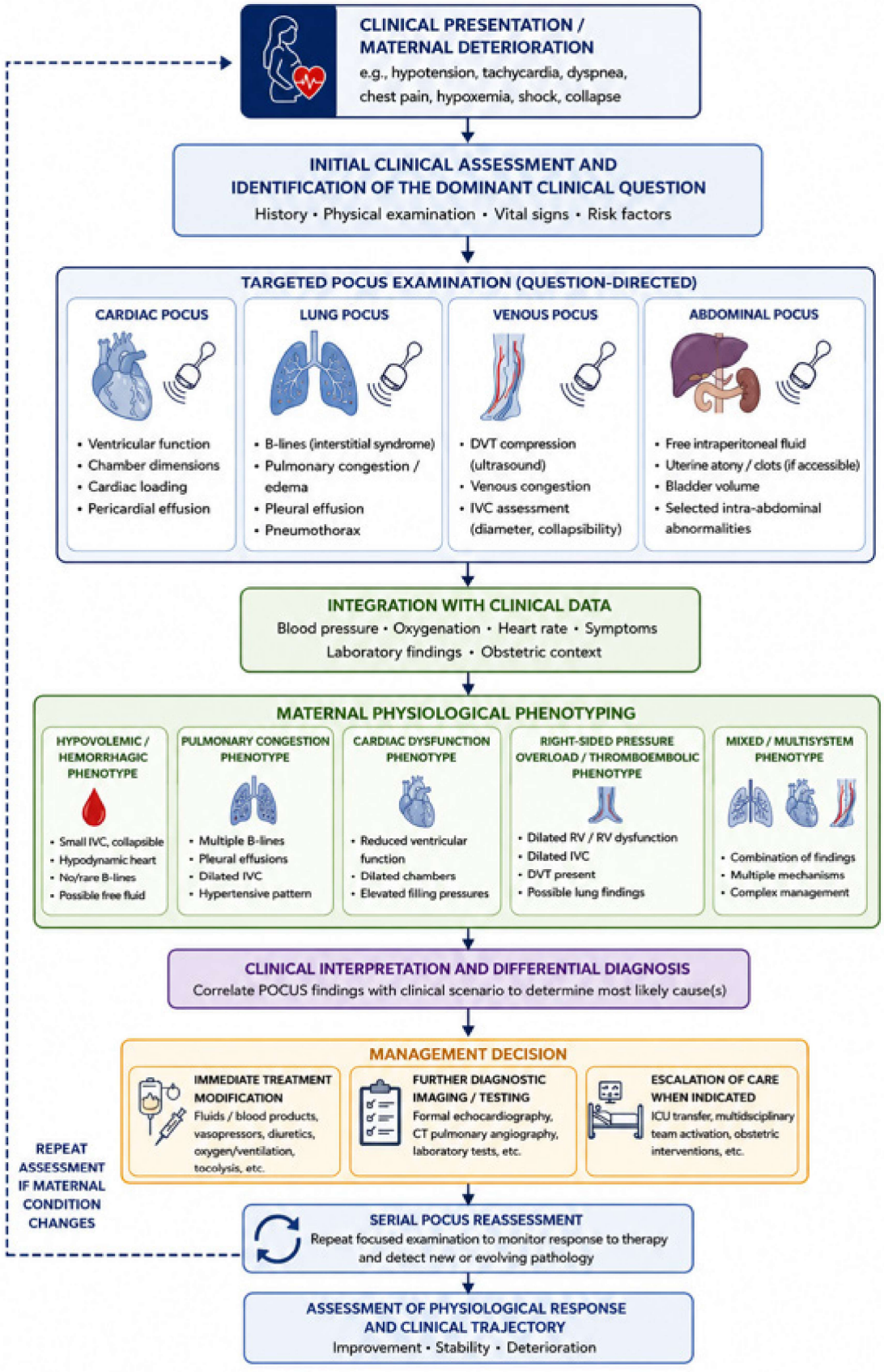

Figure 1. Proposed diagnostic and clinical decision-making algorithm for POCUS in acute obstetric care

Acronyms: DVT – deep vein thrombosis; ICU – intensive care unit; IVC – inferior vena cava; POCUS – point-of-care ultrasonography; RV – right ventricle

Future Directions

Future advancements in maternal POCUS are likely to rather rely on enhancing the temporal, quantitative, and outcome-oriented integration of bedside ultrasound into maternal acute-care pathways than increase the number of abnormalities that may be detected. The field is gradually moving from the concept of a one-time focused examination toward a model in which POCUS contributes repeatedly to characterization of changing maternal physiology, which could transform the technique from a diagnostic adjunct into a form of bedside physiological monitoring. Maternal physiological examination may become even more decentralized if handheld and ultraportable ultrasound technologies become more widely available. Emergency rooms, obstetric wards, operating rooms, recovery areas, ambulances, and maternity settings with fewer resources may be able to use focused ultrasound with smaller equipment. This decentralization could be especially important for the Bulgarian and other healthcare systems where access to tertiary and regional facilities varies, provided that it is complemented by suitable training, governance, referral mechanisms, and quality assurance. For geographically distributed healthcare systems, tele-POCUS could therefore transform ultrasound from a locally constrained diagnostic resource into a networked clinical capability, provided there is an adequate establishment of connectivity, data security, credentialing, and escalation pathways are adequately established. Future studies should therefore progress beyond diagnostic accuracy and surrogate physiological endpoints toward clinically meaningful outcomes, such as severe maternal morbidity, intensive-care admission, respiratory failure, shock, transfusion requirements, acute organ dysfunction, emergency procedures, maternal mortality, length of stay, and cost-effectiveness.

Conclusions

Point-of-care ultrasonography is a significant advancement in acute maternal assessment because it enables clinicians to gather concentrated anatomical and physiological information at the time and location where therapeutic choices are made. Its main advantage goes beyond picture acquisition: since POCUS can convert nonspecific clinical symptoms into interpretable physiological phenotypes involving the maternal cardiovascular, pulmonary, vascular, volume-related, and abdominal systems. Presently, evidence supporting the diagnostic and physiological utility of POCUS is substantially stronger than evidence demonstrating that POCUS-guided care directly improves severe maternal morbidity or mortality and, therefore, diagnostic accuracy should not be conflated with clinical effectiveness, and mechanistic plausibility should not be presented as demonstrated outcome benefit. The next phase of maternal POCUS research should therefore go beyond the question of whether ultrasound can detect disease. The more important question is whether real-time physiological phenotyping can consistently provide better therapeutic judgments and, as a result, improved mother outcomes. This transformation will call for standardized protocols, competency-based training, stringent quality assurance, multidisciplinary governance, prospective outcome studies, and suitable integration with traditional imaging.

References

1. Zhao M, Zhang S, Hong H, et al. Incremental value of immediate postpartum pocus for risk stratification of adverse maternal outcomes in hypertensive disorders of pregnancy. J Clin Med, 2026, 15(13):4989.
2. Díaz-Gómez JL, Mayo PH, Koenig SJ. Point-of-care ultrasonography. N Engl J Med, 2021, 385(17):1593-1602.
3. Lindow T, Quadrelli S, Ugander M. Noninvasive imaging methods for quantification of pulmonary edema and congestion. JACC: Cardiovascular Imaging, 2023, 16(11):1469-1484.
4. Zhang SJ, He SZ, Wu JJ, et al. Evaluation of extravascular lung water and cardiac function by intrapartum bedside ultrasound: full-term preeclampsia vs. healthy controls. Front Cardiovasc Med, 2026, 13:1709378.
5. Soliman-Aboumarie H, Breithardt OA, Gargani L, et al. How-to: focus cardiac ultrasound in acute settings. Eur Heart J Cardiovasc Imaging, 2022, 23(2):150-153.
6. Ceriani E, Schiavon R, La Cava L, et al. Point of care ultrasound: focus on evidence for a critical appraisal. Eur J Intern Med, 2025, 141:106376.
7. Rice JA, Brewer J, Speaks T, et al. The POCUS Consult: How Point of Care Ultrasound Helps Guide Medical Decision Making. Int J Gen Med, 2021, 14:9789-9806.
8. Lanspa MJ, Fox SW, Sohn J, et al. Definitive advantages of point-of-care ultrasound: a case series. CASE (Phila), 2022, 6(6):293-298.
9. Noor A, Liu M, Jarman A, et al. Point-of-care ultrasound use in hemodynamic assessment. Biomedicines, 2025, 13(6):1426.
10. D'Andrea A, Del Giudice C, Fabiani D, et al. The incremental role of multiorgan point-of-care ultrasounds in the emergency setting. IJERPH, 2023, 20(3):2088.
11. Adeniran AK, Oyetola EO, Jagunmolu HA, et al. The Role of Point-of-care Ultrasound in Cardiac Arrest; A Narrative Review. Arch Acad Emerg Med, 2025, 13(1):e68.
12. Algodi M, Wolfe DS, Taub CC. The utility of maternal point of care ultrasound on labor and delivery wards. JCDD, 2022, 9(1):29.
13. Van Der Zande JA, Rijs K, Shamshirsaz AA, et al. The role of point-of-care ultrasound (POCUS) in maternal medicine. Best Pract Res Clin Obstet Gynaecol, 2025, 100:102599.
14. Fraleigh CDM, Duff E. Point-of-care ultrasound: An emerging clinical tool to enhance physical assessment. Nurse Pract, 2022, 47(8):14-20.

15. Recker F, Weber E, Strizek B, et al. Point-of-care ultrasound in obstetrics and gynecology. Arch Gynecol Obstet, 2021, 303(4):871-876.
16. Jain V, O'Quinn C, Van Den Hof M. Guideline No. 421: Point of Care Ultrasound in Obstetrics and Gynaecology. J Obstet Gynaecol Can, 2021, 43(9):1094-1099.e1.
17. Yun HI, Wubben BM. Performance of POCUS for Pregnancy Evaluation using a Non-Piezoelectric Ultrasound Device in the Emergency Department. POCUS J, 2025, 10(2):86-90.
18. Braga A, De Melo HK, Paiva G, et al. Advances and challenges in obstetric intensive care medicine. JCM, 2026, 15(4):1487.
19. De Robertis V, Bilardo CM, Stampalija T. Point-of-care ultrasound in obstetrics and gynecology: a powerful instrument calling for standardization and validation studies. Ultrasound Obstet Gynecol, 2026, 67(6):729-734.
20. Saadi MP, Telo GH, Rasmeehirun P, et al. The rise of point-of-care ultrasound in cardiopulmonary diagnostics. Eur Heart J Imaging Methods Pract, 2026, 4(1):qyaf147.
21. Osborne AD, Corder W, Stoller JZ, et al. Technical considerations and applications of point-of-care ultrasound in the NICU. Semin Perinatol, 2026, 50(1):152190.
22. Olszewski E, Olusanya O, Olusanya S, et al. Point of care ultrasound in acute settings – a narrative review. J Global Med, 2024, 4(1):e145.
23. Poggi C, Palavecino M. Ultrasound principles and instrumentation. Surg Open Sci, 2024, 18:123-128.
24. Lu Y, Di Giacinto B. Physical principles and imaging techniques of ultrasound elastography. In: Elastography – Current Insights and Applications. Goenka M, Roy A, Goenka U (eds.). IntechOpen, 2025.
25. Kim MG, Yoon C, Lim HG. Recent Advancements in High-Frequency Ultrasound Applications from Imaging to Microbeam Stimulation. Sensors (Basel), 2024, 24(19):6471.
26. Hashim A, Tahir MJ, Ullah I, et al. The utility of point of care ultrasonography (POCUS). Ann Med Surg (Lond), 2021, 71:102982.
27. Hayward LM, Markowski AM, Steiner BUK, et al. Point of care ultrasonography in physical therapists' clinical practice: a clinical perspective. J Man Manip Ther, 33(4):334-342.
28. Cheng PJ, Hsu NC. Incorporating multiorgan point-of-care ultrasound into obstetric emergency treatment protocols. J Med Ultrasound, 2023, 31(2):83-85.
29. Tsangalis G, Loizon V. Point-of-care ultrasound (POCUS) for dialysis patients: a step forward. Kidney and Dialysis, 2022, 2(2):140-152.
30. Haskings EM, Eissa M, Allard RV, et al. Point-of-care ultrasound use in emergencies: what every anaesthetist should know. Anaesthesia, 2023, 78(1):105-118.
31. Ornellas SB, Kizilaslan B, Shah A, et al. Ultrasound in Women's Health: Mechanisms, Applications, and Emerging Opportunities. Adv Mater, 2026, 38(14):e20454.
32. Campora A, Beltrami M, Di Renzo A, et al. The role of lung ultrasound scan in different heart failure scenarios: current applications and lacks of evidences. Diagnostics, 2024, 15(1):45.
33. Ajah ON. Pulmonary embolism and right ventricular dysfunction: mechanism and management. Cureus, 16(9):e70561.
34. Grifoni S, Olivotto I, Cecchini P, et al. Short-term clinical outcome of patients with acute pulmonary embolism, normal blood pressure, and echocardiographic right ventricular dysfunction. Circulation, 2000, 101(24):2817-2822.
35. Ali N, Chhotani AA, Iqbal SP, et al. Point of care ultrasonographic life support in emergency (Pulse) —a quasi-experimental study. Int J Emerg Med, 2023, 16:49.
36. Overgaard J, Thilagar BP, Bhuiyan MN. A clinician's guide to the implementation of point-of-care ultrasound (POCUS) in the outpatient practice. J Prim Care Community Health, 2024, 15:21501319241255576.
37. Wainstein MV, Machado GP, Telo GH, et al. Point-of-care ultrasound in the evaluation of STEMI patients. Front Cardiovasc Med, 2025, 12:1627396.
38. Koratala A, Kazory A. Point of care ultrasonography for objective assessment of heart failure: integration of cardiac, vascular, and extravascular determinants of volume status. Cardiorenal Med, 2021, 11(1):5-17.
39. Bitar ZI, Elshabasy RD, Mohsen MJ, et al. Detecting spontaneous retroperitoneal hemorrhage using a modified RUSH protocol: a case report. Int J Surg Case Rep, 2022, 92:106830.
40. Soliman Aboumarie H. Cardiopulmonary point-of-care ultrasound for critical care. Clin Med (Lond), 2026, 26(4):100624.
41. Polyzogopoulou E, Velliou M, Verras C, et al. Point-of-care ultrasound: a multimodal tool for the management of sepsis in the emergency department. Medicina (Kaunas). 2023, 59(6):1180.
42. Dias Souza M, Rahhal H, Tibério IFLC. Assessing the clinical relevance of point-of-care ultrasound for hospitalists: Influence on clinical reasoning and decision-making. PLoS One, 2025, 20(12):e0338202.
43. Githemo G, Wanyoro A, Masika J, et al. Evaluation of large-scale implementation of obstetric point of care ultrasound in eight counties in Kenya using RE-AIM framework. BMC Health Serv Res, 2025, 25:1016.
44. Ramlakhan KP, Malhamé I, Marelli A, et al. Hypertensive disorders of pregnant women with heart disease: the ESC EORP ROPAC Registry. Eur Heart J, 2022, 43(38):3749-3761.
45. Afify H, Kong A, Bernal J, et al. Pulmonary hypertension in pregnancy: challenges and solutions. Integr Blood Press Control, 2022, 15:33-41.
46. Hofmann R, Blaskova LJ, Jones N. A theory-informed approach to identify barriers to utilising Point-of-Care Ultrasound (POCUS) in practice: from vicious cycles to sustainable solutions. Adv Health Sci Educ Theory Pract, 2026, 31(2):373-398.
47. Xu Z, Lian H, Ren X. Education and training models for point-of-care ultrasound in perioperative medicine: a narrative review. Front Med (Lausanne), 2026, 13:1873520.
48. Fox S, Fleshner M, Flanagan C, et al. Developing and Evaluating a Remote Quality Assurance System for Point-of-Care Ultrasound for an Internal Medicine Residency Global Health Track. POCUS J, 2020, 5(2):46-54.
49. Li Y, Wang H, Yuan K, et al. Effectiveness of obstetric point-of-care ultrasound (POCUS) training: a systematic review and meta-analysis based on the ADDIE training model. Ultrasound J, 2025, 17(1):67.
50. Mouser C. Taking the next step in obstetric critical care: cardiac and lung pocus training for obstetric residents. POCUS Journal, Accessed August 14, 2026, https://pocusjournal.com/article/19976/

Received: August 17th 2026.