CASE REPORTS
КЛИНИЧНИ СЛУЧАИ

Eosinophilic pustular folliculitis in childhood

R. Markova[1], J. Kazandjieva[2]

[1]First Pediatric Consultative Clinic – Sofia, Medical University – Pleven
[2]EuroDerma Clinic – Sofia

Еозинофилен пустулозен фоликулит при дете

Р. Маркова[1], Ж. Казанджиева[2]

[1]Първа Детска Консултативна клиника – София, Медицински Университет – Плевен
[2]Клиника „ЕвроДерма“ – София

Abstract:	Eosinophilic pustular folliculitis in children (EPF) was first described in 1984. The disease occurs in young children. It is characterized by the appearance of isolated or grouped sterile pustules containing eosinophils and eosinophilia in the peripheral blood. A clinical case of a boy with eosinophilic pustular folliculitis is presented, along with literature data on the disease, which, although quite rare, is important to be aware of by pediatricians and clinical dermatologists.
Key words:	eosinophilic folliculitis, childhood
Address for correspondence:	*Assoc. Prof. Rada Markova, MD, PhD, e-mail: rada_markova@yahoo.com*
Резюме:	Еозинофилният пустулозен фоликулит при деца (ЕПФД) е описан за първи път през 1984 г. Заболяването се наблюдава при малки деца. Характеризира се с появата на изолирани или групирани стерилни пустули, съдържащи еозинофили и еозинофилия в периферната кръв. Представен е клиничен случай на момче с еозинофилен пустулозен фоликулит и литературни данни за заболяването, което, въпреки че е доста рядко, е важно да се познава от педиатрите и клиничните дерматолози.
Ключови думи:	еозинофилен фоликулит, детска възраст
Адрес за кореспонденция:	*Доц. д-р Рада Маркова, дм, e-mail: rada_markova@yahoo.com*

Introduction

Eosinophilic pustular folliculitis in children (EPF) was first described in 1984 [1]. The disease is observed in young children up to 36 months of age [2]. It is characterized by the appearance of isolated or grouped sterile pustules containing eosinophils and eosinophilia in the peripheral blood. It is usually localized on the scalp, but can also affect other parts of the body, such as the face, neck, truncus and limbs. More unusual clinical manifestations, such as acrosyringeal palmoplantar location of the pustules, have also been described [3].

The spectrum of eosinophilic pustular dermatoses includes three clinical variants:

– Classic eosinophilic pustular folliculitis (Ofuiji disease)

– Eosinophilic pustular folliculitis in children [4]

– Eosinophilic pustular folliculitis associated with immunosuppression (IS-EPF) – in patients with HIV and hematological neoplastic diseases

Medication-induced eosinophilic pustular folliculitis has also been described, but this form has not yet been separated into a new clinical variant [5].

The histological finding is identical in all eosinophilic pustular dermatoses – eosinophilic infiltration of the hair follicles [6]. Eosinophilic infiltrates, characteristic of all forms, are probably an indicator of allergic inflammation and it is assumed that an aberrant immune response is at the basis of this process [7].

Clinical case

The patient is a 4-year-old boy. The child was born from a normal pregnancy, forceps delivery, with evidence of external hydrocephaly. Delayed physical and neuropsychological development with later walking and talking and severe hyperhidrosis is observed. According to the medical history, acute urticaria was observed in the child after taking hazelnut Tahhan and basilic pesto. Hypospadias was found as a concomitant pathology. Family history reveals hay fever in both parents.

After 6 months of age, the child developed rashes on the scalp and feet. The skin manifestations were chronic-relapsing and very itchy. The dermatological status was represented by erythematous papules and multiple pustules located on the scalp (Figs. 1, 2) and on the plantar and lateral surfaces of both feet (Figs. 3-7). The pustules were of different sizes, with a yellowish content, located on an erythematous base. The complete blood count showed pronounced eosinophilia - up to 10-12%, the other indicators were normal. The child also had several episodes of obstructive bronchitis.

The diagnosis: “Eosinophilic pustular folliculitis” was made based on the scalp involvement, tissue eosinophilia and the chronic-relapsing course of the disease.

Treatment was carried out with Xyzal drops 2x5 drops/day and Diprogenta cream. An excellent response to the therapy was observed (Fig. 8-9), but within a year and a half several more relapses of the skin changes appeared.



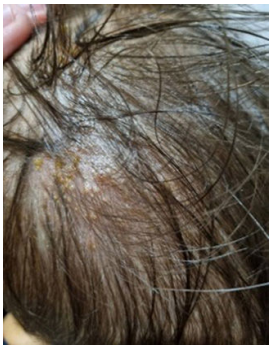

Fig. 1-2 – pustules on an erythematous base, located in the scalp area



Fig. 3-7 – pustular rash on the feet





Fig. 8-9 – current view – without pathological changes

Discussion

Eosinophilic pustular folliculitis (EPF) is an inflammatory dermatosis of unknown etiology and chronic relapsing course [8]. The disease is rare, its exact global incidence is unknown, and there is a large geographic and demographic diversity according to the respective variant. Males are more often affected than females [9]. The typical clinical manifestation includes sterile follicular pustules or papules on an erythematous base. Papulopustular lesions can be isolated or grouped, often with secondary crusting. They are intensely pruritic, and reverse development is observed after 1-4 weeks. Postlesional localized hyperpigmentation is often observed. Papules appear most often on the face, scalp, neck and torso and can persist for weeks or months. The appearance of papules and pustules on the palms and soles has been described in the scientific literature [10]. Some authors believe that eosinophilic pustules on the palms and soles are anatomically related to the eccrine apparatus [11]. Similar findings have been demonstrated in neutrophilic pustules in palmoplantar pustulosis. The intraepidermal eccrine ducts are likely the sites affected by eosinophilic infiltration in palmoplantar lesions of EPF [5].

The clinical characteristics of the lesions and laboratory tests are of great importance for establishing the correct diagnosis. Skin biopsy is the most accurate diagnostic test. Histopathologically, eosinophils are found under the epidermis and around the hair follicles and sebaceous glands. In many cases, blood tests show a slight increase in eosinophil cells and immunoglobulin-E (IgE), as well as reduced levels of IgG and IgA. Pruritus and eosinophilia are present in the majority of patients. Eosinophilia usually increases during active skin exacerbations.

Eosinophilic pustular folliculitis can be a clinical manifestation of immunodeficiency [12]. This clinical variant, associated with HIV infection, occurs when CD4 + lymphocyte cell levels fall below 300 cells/mm3 – a level at which there is an increased risk of secondary opportunistic infection. Cases of eosinophilic pustular folliculitis have also been reported after bone marrow transplantation, before the immune system has returned to normal function, and in patients with hereditary immune deficiencies.

Recognition of the condition and its distinction from other types of pustular lesions is crucial to avoid unnecessary diagnostic procedures and inappropriate treatment, especially in vulnerable groups of children, such as premature infants. The diagnosis should be considered in newborns or infants with papulopustular eruptions.

The differential diagnosis between the main two variants of the disease is shown in Table 1.

Other differential diagnoses that should be excluded include toxic erythema of the newborn, bacterial, viral, and fungal infections, transient neonatal pustular dermatosis, infantile acropustulosis, Langerhans' histiocytosis, and Hyper-IgE syndrome.

There are no established treatment guidelines for EPF [13]. The disease does not require aggressive treatment and usually responds to symptomatic therapy. However, 90% of cases respond well to mild to moderate topical corticosteroids. Antibiotics are ineffective in the treatment of EPF itself, but are appropriate if secondary infection of the lesions occurs. Other treatment options include topical tacrolimus and oral antihistamines. In refractory cases, dapsone, erythromycin, and indomethacin have been suggested as alternative methods of therapeutic intervention.

The fact that eosinophilic pustular folliculitis responds to such a diverse array of treatment modalities, including immunosuppressive drugs, antimicrobial agents, and phototherapy, suggests that the pathogenesis of the disease is multifactorial. The complex interplay between immune dysregulation, microbial factors, and likely genetic predisposition warrants further research to unravel the complex etiological mechanisms and refine therapeutic strategies.

Table 1. Main differential diagnostic criteria between the variants of eosinophilic pustular folliculitis

Clinical characteristics EPF		Classical Ofuji disease
Start	up to 3 years of age	20-40 years of age
Localization of primary lesions	scalp, face, neck	Face, trunk, upper limbs
Systemic involvement	Peripheral eosinophilia	Peripheral eosinophilia, elevated IgE
Clinical course	Benign, usually resolvesby the third year	chronic-recurrent, lasts for years

References

1. Lucky AW, Esterly NB, Heskel N, et al. Eosinophilic pustular folliculitis in infancy. Pediatr Dermatol. 1984;1:202-206.
2. Hernández-Martín Á, Nuño-González A, Colmenero I, et al. Eosinophilic pustular folliculitis of infancy: a series of 15 cases and review of the literature. J Am Acad Dermatol. 2013;68(1):150-155.
3. Aoyama H, Tagami H. Eosinophilic pustular folliculitis starting initially only with palmoplantar pustular lesions. Report of a case and review of the literature. Dermatology 1992; 185: 276-280.
4. Frølunde AS, Olesen AB, Riber-Hansen R, et al. Eosinophilic pustular folliculitis of infancy: A rare diagnosis in children. Clin Case Rep. 2021; 11 (5):e04167.
5. Smith SS, Cernaro N, Tonti E. Eosinophilic pustular folliculitis due to naltrexone: A case report. J Am Pharm Assoc. 2022;62(6):1925-1928.
6. Fertitta L, Bodemer Ch, Molina Th, et al. Eosinophilic Pustular Folliculitis of Infancy: A Histologic Assessment of 43 Cases. Am J Dermatopathol.2022;44(6): 395-403..
7. Marina S, Savova J, Kirov G. Idiopatichni eozinofilni sindromi. Computerart, S., 2001.
8. Katoh M, Nomura T, Miyachi Y, et al. Eosinophilic pustular folliculitis: a review of the Japanese published works. J Dermatol. 2013;40(1):15-20.
9. Takematsu H, Nakamura K, Igarashi M, et al. Eosinophilic pustular folliculitis. Report of two cases with a review of the Japanese literature. Arch Dermatol. 1985;121(7):917-920.
10. Satoh T, Ikeda H, Yokozeki H. Acrosyringeal involvement of palmoplantar lesions of eosinophilic pustular folliculitis. Acta Derm Venereol. 2013;93(1):99.
11. Tsuboi H, Niiyama S, Katsuoka K. Eosinophilic pustular folliculitis (Ofuji disease) manifested as pustules on the palms and soles. Cutis. 2004;74(2):107-110.
12. Cedeno-Laurent F, Gómez-Flores M, Mendez N, et al. New insights into HIV-1-primary skin disorders. J Int AIDS Soc. 2011; 24:14-15.
13. Ellis E, Scheinfeld N. Eosinophilic pustular folliculitis: a comprehensive review of treatment options. Am J Clin Dermatol. 2004;5(3):189-197.

Received: June 25th 2026.