Reed nevus or nodular melanoma? a diagnostic challenge in a 15-year-old girl

S. Kordeva[1], K. G. Tchernev Jr[1], V. Broshtilova[2], G. Tchernev[1,3]

[1]Onkoderma – Clinic for Dermatology, Venereology and Dermatologic Surgery
[2]Department of Internal Diseases, Pharmacology and Clinical Pharmacology, Pediatrics, Epidemiology, Infectious Diseases, and Skin Diseases, Faculty of Medicine, Sofia University "Sv. Kliment Ohridski"
[3]Department of Dermatology and Venereology, Medical Institute of Ministry of Interior, Sofia

Невус на Рийд или нодуларен меланом? Диагностично предизвикателство при 15-годишно момиче

С. Кордева[1], К. Г. Чернев-младши[1], В. Брощилова[2], Г. Чернев[1,3]

[1]Онкодерма – Клиника по дерматология, венерология и дерматологична хирургия
[2]Катедра по вътрешни болести, фармакология и клинична фармакология, педиатрия, епидемиология, инфекциозни болести и кожни болести, Медицински факултет, Софийски университет „Св. Климент Охридски"
[3]Катедра по дерматология и венерология, Медицински институт на МВР, София

Abstract:

Reed nevus, also known as pigmented spindle cell nevus (PSCN), is a distinctive benign melanocytic lesion that may exhibit clinical, dermoscopic, and histopathological features resembling malignant melanoma. It typically affects younger individuals, particularly women, and is most commonly located on the lower extremities. In the pediatric population, these lesions may raise particular concern due to their alarming initial appearance and the potential for clinical features suggestive of malignancy. Although various diagnostic markers are available, they may not always reliably distinguish benign, atypical, and malignant lesions, especially during the proliferative phase, when melanocytic lesions can demonstrate features that mimic more aggressive neoplasms. Therefore, surgical excision remains the gold standard for lesions with persistent diagnostic uncertainty. We present the case of a 15-year-old girl with rapidly growing, asymmetric pigmented nodular papule located on the lateral aspect of the right pretibial region. Based on the clinical and dermoscopic findings, the lesion was considered an atypical melanocytic lesion with a high suspicion for spitzoid or nodular melanoma. Surgical excision was performed, and subsequent histopathological examination confirmed the diagnosis of Reed nevus.

Key words: Reed nevus, malignant melanoma, pretibial lesion, surgical excision

Address for correspondence: *Prof. Georgi Tchernev, MD, e-mail: georgi_tchernev@yahoo.de*

Резюме:

Невусът на Рийд, известен още като пигментиран вретенообразноклетъчен невус (PSCN), е характерно доброкачествено меланоцитно образувание, което може да проявява клинични, дерматоскопски и хистопатологични характеристики, наподобяващи злокачествен меланом. Обикновено засяга по-млади хора, особено жени, като най-често се локализира по долните крайници. При децата тези лезии могат да предизвикат особено притеснение поради тревожния им първоначален вид и възможността за клинични признаци, насочващи към злокачествено заболяване. Въпреки че са налице различни диагностични маркери, те не винаги могат надеждно да разграничат доброкачествените, атипичните и злокачествените лезии, особено по време на пролиферативната фаза, когато меланоцитните лезии могат да проявяват характеристики, наподобяващи по-агресивни неоплазми. Поради това хирургичното отстраняване остава „златният стандарт" за лезии с продължаваща диагностична несигурност. Представяме случая на 15-годишно момиче с бързо нарастваща, асиметрична пигментирана нодуларна папула, разположена на латералната повърхност на дясната предтибиална област. Въз основа на клиничните и дерматоскопските данни лезията беше оценена като атипична меланоцитна лезия с висока степен на подозрение за спицоиден или нодуларен меланом. Беше извършена хирургична ексцизия, а последвалото хистопатологично изследване потвърди диагнозата невус на Рийд.

Ключови думи: невус на Рийд, злокачествен меланом, претибиална лезия, хирургично отстраняване

Адрес за кореспонденция: *Проф. д-р Г. Чернев, e-mail: georgi_tchernev@yahoo.de*

Introduction

Reed nevus, also known as pigmented spindle cell nevus (PSCN), is a distinctive melanocytic lesion that may exhibit clinical and histopathological features resembling malignant melanoma [1]. PSCN typically presents as a small lesion, usually less than 7 mm in diameter, occurring predominantly in younger individuals, particularly women, and most commonly located on the lower extremities [1]. In contrast, spindle cell malignant melanomas (SCMMs) are more frequently encountered on the trunk, upper extremities, and in the head and neck regions [1].

Clinical and dermoscopic features of small Reed nevi measuring less than 6 mm may overlap with those of melanoma, making accurate assessment challenging [2]. During the early stages of evolution, these lesions typically exhibit a globular pattern, particularly in childhood, followed by the characteristic starburst pattern [2]. Nevertheless, some lesions remain difficult to distinguish from malignant melanoma and are therefore often considered for surgical excision, as clinical and dermoscopic evaluation alone may be insufficient to reliably predict the presence of histopathological atypia or exclude malignancy [3].

Case report

A 15-year-old girl presented to the Dermatology Department with a primary complaint of a pigmented nodule located on the right lower extremity. According to the patient's history, the lesion had been present as a small pigmented macule since early childhood but had demonstrated noticeable growth during the preceding months.

Dermatological examination revealed a rapidly growing, asymmetric pigmented nodular papule located on the lateral aspect of the right pretibial region. The lesion exhibited dense black-brown pigmentation with a focal area of lighter pigmentation on one side (Figure 1a, 1b). Dermoscopic examination demonstrated uneven peripheral radial streaks. Based on the clinical and dermoscopic findings, the lesion was considered an atypical melanocytic lesion with a high suspicion for spitzoid or nodular melanoma.



Fig. 1a, 1b: Preoperative view: A rapidly growing, asymmetric pigmented nodular papule located on the lateral aspect of the right pretibial region. The lesion exhibited dense black-brown pigmentation with a focal area of lighter pigmentation on one side

The patient was scheduled for surgical excision of the lesion. Routine laboratory investigations were within the normal range.

The lesion was excised with an elliptical excision with 3 mm surgical margins in all directions under local anesthesia with 1% lidocaine. Wound closure was achieved with single 3-0 polypropylene interrupted sutures (Figure 2).



Fig. 2: Intraoperative view: The lesion is excised and the wound edges were adapted using single interrupted sutures

Histopathological examination revealed an asymmetric, well-circumscribed melanocytic lesion characterized by orthohyperkeratosis alternating horizontally with parakeratosis and filiform pigmented inclusions.

A compact proliferation of fusiform melanocytes forming nests of varying sizes that consume the overlying epidermis and obscure the dermo-epidermal junction, demarcated by a moderately pronounced lympho-plasmacytic stromal response (Figure 3a). Surgical resection margins were clear. Immunohistochemical analysis demonstrated diffuse p16 expression throughout 100% of the melanocytic population (Figure 3b), while the Ki-67 proliferative index was below 5% (Figure 3c). The histological and immunohistochemical findings were consistent with a pigmented spindle cell nevus (Reed nevus).

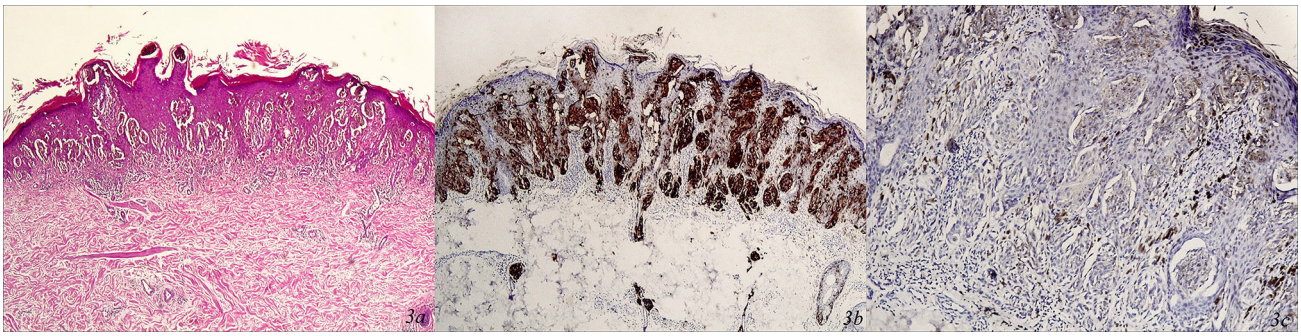

Fig. 3a-c: Histology panel

3a: Nevus Reed x 40 x HE: an asymmetric, well-circumscribed melanocytic lesion characterized by orthohyperkeratosis alternating horizontally with parakeratosis and filiform pigmented inclusions. A compact proliferation of fusiform melanocytes forming nests of varying sizes that consume the overlying epidermis and obscure the dermo-epidermal junction, demarcated by a moderately pronounced lympho-plasmacytic stromal response

3b: Nevus Reed x 40 x p16: diffuse p16 expression throughout 100% of the melanocytic population

3c: Nevus Reed x 100 x ki67: Ki-67 proliferative index is below 5%

Discussion

Pigmented spindle cell nevus, also known as Reed nevus, is a benign pigmented variant of spindle cell Spitz nevus that occurs predominantly on the lower extremities [4]. Histopathologically, it is composed of elongated spindle-shaped melanocytes and nevoid cells and exhibits a benign clinical course [5].

Although some authors regard Reed nevus as a distinct entity that may overlap with cutaneous melanoma in both clinical and dermoscopic features [6], it shares several characteristics with Spitz nevi and, in contrast to malignant melanoma, typically exhibits a small size, lesion symmetry, cellular uniformity, well-defined circumscription, and maturation of cells from the superficial to the deeper layers [5].

Compared with a classical Spitz nevus, a Reed nevus is usually more heavily pigmented and contains many melanophages [5]. Although most Reed nevi are deeply pigmented, cases of hypopigmented variants have been reported [7]. Histologically, Reed nevi exhibit abundant coarse melanin granules within the lesional melanocytes and keratinocytes (5). The melanocytic proliferation is typically confined to the papillary dermis and dermoepidermal junction, whereas Spitz nevi often extend into the reticular dermis [5].

According to the literature, PSCN typically exhibits the “starburst dermatoscopic pattern”, characterized by prominent diffuse dark pigmentation and peripheral radial streaks, whereas Spitz nevi are more commonly associated with a “globular pattern” consisting of central light brown, grey or blue pigmentation surrounded by a rim of large brown globules [5, 8].

According to Argenziano et al. [9], additional dermoscopic features may help distinguish pigmented spindle and/or epitheloid cell nevi from cutaneous melanoma. The authors described a superficial black network observed in 10.5% of these lesions, which histologically corresponds to focal areas of pigmented parakeratosis that produce a black reticulated appearance on the horizontal plane [9]. In our case, however, the dermatoscopic findings were inconclusive, with neither a starburst nor a globular pattern identified.

Differential diagnoses may include dysplastic nevus, spindle cell nodular malignant melanoma, and superficially spreading malignant melanoma [5].

Despite its benign clinical behavior, Reed nevus can mimic cutaneous melanoma clinically, dermoscopically, and even histopathologically [10]. In such cases, immunohistochemical markers, including Ki-67, cyclin D1, and survivin, may provide additional diagnostic information. Ki-67 positivity in Reed nevus is typically below 2-5% and largely confined to the epidermal junction, whereas melanoma usually exhibits a substantially higher proliferative index, with

cells extending deep within the tissue [11]. Nevertheless, these markers should be interpreted as additional tools, as their expression may overlap between lesions and can be elevated during the growth phase of melanocytic lesions [12].

In cases showing elevated marker levels and borderline architectural features, the lesion may be classified as atypical Spitzoid tumor, and additional fluorescence in situ hybridization (FISH) testing can be performed to further evaluate for the possibility of melanoma [11]. P53 immunolabeling may also be used alongside Ki-67 as an additional marker for identifying the vertical growth phase in nodular malignant melanoma [13].

For lesions demonstrating pagetoid and adnexal spread, HMB-45 immunostaining may serve as a useful diagnostic tool when interpreted within the appropriate clinicopathological context [5, 14].

In pediatric patients, the possibility of malignancy must be carefully assessed; even when dermoscopic findings strongly suggest a Spitz/Reed nevus, histopathological features of atypia may still be present [3]. In a study by Pedrosa et al. [3], 28 pediatric patients underwent surgical excision, with 8 cases (28.6%) demonstrating at least one histopathological criterion for atypia.

According to some authors, Spitz/Reed nevi should be excised in adults and in children older than 12 years of age, given the inability to reliably identify lesions with histopathological atypia that may pose a diagnostic challenge in the differential diagnosis with spitzoid melanoma [3, 15].

Nevertheless, even with the use of diagnostic markers, establishing the correct diagnosis remains dependent on histopathological examination following excision. When clinical and dermoscopic findings are inconclusive, complete surgical excision remains the gold standard for lesions with uncertain malignant features [10].

Conclusions

Complete surgical excision remains the most appropriate and reliable approach when the biological behavior of the lesion cannot be confidently determined. Although not all cases align with the established criteria, in situations of diagnostic uncertainty, management decisions should be guided by the principle of minimizing risk while maximizing patient benefit.

The authors declare no conflict of interest.

Ethics approval statement is not required.

Written informed consent for publication of their details was obtained from the patient.

References

1. Díaz A, Valera A, Carrera C, et al. Pigmented spindle cell nevus: clues for differentiating it from spindle cell malignant melanoma. A comprehensive survey including clinicopathologic, immunohistochemical, and FISH studies. Am J Surg Pathol. 2011 Nov;35(11):1733-42. doi: 10.1097/PAS.0b013e318229cf66.
2. De Giorgi V, Savarese I, Rossari S, et al. Clinical and dermoscopic features of small Reed nevus (<6 mm). J Eur Acad Dermatol Venereol. 2013 Jul;27(7):919-21. doi: 10.1111/j.1468-3083.2012.04457.x. Epub 2012 Feb 10.
3. Pedrosa AF, Lopes JM, Azevedo F, Mota A. Spitz/Reed nevi: a review of clinical-dermatoscopic and histological correlation. Dermatol Pract Concept. 2016 Apr 30;6(2):37-41. doi: 10.5826/dpc.0602a07.
4. Ferrara G, Argenziano G, Soyer HP, et al. The spectrum of Spitz nevi: a clinicopathologic study of 83 cases. Arch Dermatol. 2005 Nov;141(11):1381-7. doi: 10.1001/archderm.141.11.1381.
5. Morkin MI, Kapadia MK, Laver NV. Pigmented Spindle Cell Nevus of Reed of the Eyelid. Ocul Oncol Pathol. 2017 Sep;3(3):176-180. doi: 10.1159/000454864. Epub 2017 Jan 27.
6. Webber SA, Siller G, Soyer HP. Pigmented spindle cell naevus of Reed: a controversial diagnostic entity in Australia. Australas J Dermatol. 2011 May;52(2):104-8. doi: 10.1111/j.1440-0960.2011.00743.x. Epub 2011 Mar 24.
7. Requena C, Requena L, Sánchez-Yus E, et al. Hypopigmented Reed nevus. J Cutan Pathol. 2008 Oct;35 Suppl 1:87-9. doi: 10.1111/j.1600-0560.2007.00957.x. Epub 2008 Jun 28.
8. Argenziano G, Scalvenzi M, Staibano S, et al. Dermatoscopic pitfalls in differentiating pigmented Spitz naevi from cutaneous melanomas. Br J Dermatol. 1999 Nov;141(5):788-93. doi: 10.1046/j.1365-2133.1999.03150.x.
9. Argenziano G, Soyer HP, Ferrara G, et al. Superficial black network: an additional dermoscopic clue for the diagnosis of pigmented spindle and/or epithelioid cell nevus. Dermatology. 2001;203(4):333-5. doi: 10.1159/000051784.
10. Ferrara G, Gianotti R, Cavicchini S, et al. Spitz nevus, Spitz tumor, and spitzoid melanoma: a comprehensive clinicopathologic overview. Dermatol Clin. 2013 Oct;31(4):589-98, viii. doi: 10.1016/j.det.2013.06.012.
11. Díaz A, Valera A, Carrera C, et al. Pigmented spindle cell nevus: clues for differentiating it from spindle cell malignant melanoma. A comprehensive survey including clinicopathologic, immunohistochemical, and FISH studies. Am J Surg Pathol. 2011 Nov;35(11):1733-42. doi: 10.1097/PAS.0b013e318229cf66.
12. Lebe B, Pabuççuoğlu U, Ozer E. The significance of Ki-67 proliferative index and cyclin D1 expression of dysplastic nevi in the biologic spectrum of melanocytic lesions. Appl Immunohistochem Mol Morphol. 2007 Jun;15(2):160-4. doi: 10.1097/01.pai.0000209868.58699.64.
13. Kaleem Z, Lind AC, Humphrey PA, et al. Concurrent Ki-67 and p53 immunolabeling in cutaneous melanocytic neoplasms: an adjunct for recognition of the vertical growth phase in malignant melanomas? Mod Pathol. 2000 Mar;13(3):217-22. doi: 10.1038/modpathol.3880040.
14. Bergman R, Dromi R, Trau H, et al. The pattern of HMB-45 antibody staining in compound Spitz nevi. Am J Dermatopathol. 1995 Dec;17(6):542-6. doi: 10.1097/00000372-199512000-00002.
15. Lallas A, Moscarella E, Longo C, et al. Likelihood of finding melanoma when removing a Spitzoid-looking lesion in patients aged 12 years or older. J Am Acad Dermatol. 2015 Jan;72(1):47-53. doi: 10.1016/j.jaad.2014.09.037. Epub 2014 Oct 16.

Received: August 6th 2026.