Polypharmacy and human/skin carcinogenesis: cutaneous melanoma and laryngeal carcinoma after beta-blockers, angiotensin II receptor blockers, thiazide diuretics and centrally acting antihypertensive agents' intake – nitrosogenesis and nitroso-photocarcinogenesis as triggering factors

S. Kordeva[1], K. G. Tchernev Jr[2], V. Broshtilova[3], G. Tchernev[1,2]

[1]Department of Dermatology and Venereology, Medical Institute of Ministry of Interior
[2]Onkoderma – Clinic for Dermatology, Venereology and Dermatologic Surgery
[3]Department of Internal Diseases, Pharmacology and Clinical Pharmacology, Pediatrics, Epidemiology, Infectious Diseases, and Skin Diseases, Faculty of Medicine, Sofia University "Sv. Kl. Ohridski"

Полифармация и човешка/кожна карциногенеза: меланом на кожата и карцином на ларинкса след прием на бета-блокери, блокери на ангиотензин II рецепторите, тиазидни диуретици и антихипертензивни средства с централно действие – нитрозогенезата и нитрозофотоканцерогенезата като провокиращи фактори

С. Кордева[1], К. Г. Чернев-младши[2], В. Брощилова[3], Г. Чернев[1,2]

[1]Катедра по дерматология и венерология, Медицински институт на МВР
[2]Онкодерма – Клиника по дерматология, венерология и дерматологична хирургия
[3]Катедра по вътрешни болести, фармакология и клинична фармакология, педиатрия, епидемиология, инфекциозни болести и кожни болести, Медицински факултет, Софийски университет „Св. Кл. Охридски"

Abstract: Polypharmacy and human carcinogenesis seem to be increasingly associated. In an era of rising cancer incidence, consideration of a potential pathogenetic link between extensive medication exposure and carcinogenesis may be warranted, particularly with regard to identifying potentially preventable contributing factors. Recently, emerging data have led to new hypotheses involving exogenous and endogenous nitrosogenesis. Within the context of environmental chemical carcinogenesis, these mechanisms may provide a potential explanation for the rising incidence of cancer, including both cutaneous malignancies and solid tumors. We present the case of an 80-year-old male patient who developed both cutaneous melanoma and laryngeal carcinoma following the initiation of long-term systemic therapy with nebivolol, telmisartan, hydrochlorothiazide and moxonidine. These medications contain secondary and/or tertiary amine functional groups or possess the potential to generate such nitrosatable sites. These sites may easily undergo nitrosation, resulting in the formation of N-nitrosamine compounds, which are known to exhibit phototoxic and genotoxic properties.

Key words: skin cancer, human carcinogenesis, cutaneous melanoma, solid cancer, laryngeal carcinoma, antihypertensive therapy, polypharmacy, multimedication regimen, secondary amine, tertiary amine, nitrosogenesis, photo nitrosogenesis, chemical carcinogenesis, environmental carcinogens, exogenous nitrosation, endogenous nitrosation, photodecomposition, nebivolol, N-nitroso-nebivolol, telmisartan, N-nitrosodiethylamine (NDEA), N-nitrosodimethylamine (NDMA), hydrochlorothiazide, N-nitroso-hydrochlorothiazide, moxonidine

Address for correspondence: *Prof. Georgi Tchernev, MD, e-mail: georgi_tchernev@yahoo.de*

Резюме:

Полифармацията и канцерогенезата при хората изглеждат все по-тясно свързани. В епоха на нарастваща честота на онкологичните заболявания е уместно да се разгледа потенциална патогенетична връзка между продължителната употреба на множество лекарства и канцерогенезата, особено с оглед идентифицирането на потенциално предотвратими рискови фактори. Наскоро появили се данни доведоха до формулирането на нови хипотези, свързани с екзогенната и ендогенната нитрозогенеза. В контекста на канцерогенезата, предизвикана от химични агенти в околната среда, тези механизми могат да предложат възможно обяснение за нарастващата честота на раковите заболявания, включително както на кожните злокачествени новообразувания, така и на солидните тумори. Представяме клиничен случай на 80-годишен пациент, при когото се развиват едновременно кожен меланом и карцином на ларинкса след започване на продължителна системна терапия с небиволол, телмисартан, хидрохлоротиазид и моксонидин. Тези лекарствени средства съдържат функционални групи от типа на вторични и/или третични амини или притежават потенциала да генерират участъци, подлежащи на нитрозиране. Тези участъци могат лесно да претърпят нитрозиране, което води до образуването на N-нитрозаминни съединения, известни със своите фототоксични и генотоксични свойства.

Ключови думи:

рак на кожата, канцерогенеза при човека, кожен меланом, солиден тумор, карцином на ларинкса, антихипертензивна терапия, полифармация, режим с множество лекарства, вторичен амин, третичен амин, нитрозогенеза, фотонитрозогенеза, химична канцерогенеза, канцерогени от околната среда, екзогенна нитрозация, ендогенна нитрозация, фоторазпад, небиволол, N-нитрозо-небиволол, телмисартан, N-нитрозодиетиламин (NDEA), N-нитрозодиметиламин (NDMA), хидрохлоротиазид, N-нитрозо-хидрохлоротиазид, моксонидин

Адрес за кореспонденция:

Проф. д-р Георги Чернев, e-mail: georgi_tchernev@yahoo.de

Introduction

Nitrosamines have been described as photolabile compounds since the 1930s and may undergo photodegradation upon exposure to ultraviolet (UV) radiation, due to the inherent instability of the nitroso group – a property, which is independent of their carcinogenic potential [1, 2].

Nearly 90 years later, it is now recognized that the photodegradation, or more precisely, photodecomposition, of nitrosamines may be accompanied by the release of nitric oxide (NO), which can interact with reactive oxygen species (ROS) and contribute to DNA damage [3]. This mechanism may represent the missing component of human carcinogenesis, potentially contributing to the development and/or progression of both skin cancer, melanoma for example, and solid tumors [3, 4]. Additionally, a chronic inflammatory microenvironment promotes the generation of ROS, which can disrupt normal cellular signaling pathways, induce DNA damage and genomic instability, and promote the survival and progression of malignant cells [5].

Nowadays, these mechanisms are increasingly being recognized as relevant components of the environmental chemical human carcinogenesis [6]. Since 2017, certain medications, such as angiotensin-converting-enzyme inhibitors (ACEi), angiotensin-receptor blockers (ARBs), and thiazides, have been associated with an increased risk of cutaneous neoplasms [7]. Nearly a decade later, emerging evidence suggests that the potential carcinogenic factor may not be the parent drug itself, but rather nitrosamine compounds, which may be formed from their generic structure, particularly those containing secondary, tertiary, or quaternary amine functional groups within their chemical structure [8].

Drug nitrosation has emerged as an important and increasingly recognized concern in the context of human carcinogenesis [8]. The potential carcinogenic risk may not be attributed solely to pre-existing nitrosamine contamination of pharmaceutical products, but also to the exogenous and/or endogenous formation of N-nitrosamines from susceptible pharmaceutical compounds [8].

In this context, we present another confirmative case of a patient who developed laryngeal carcinoma and superficial spreading malignant melanoma in the regio deltoidalis anterior sinistra in the context of long-term use of polymedication. The medication regimen included nebivolol, telmisartan/hydrochlorothiazide, and moxonidine.

The potential role of environmental chemical carcinogenesis associated with dietary and pharmaceutical exposures will be discussed in the context of human carcinogenesis, with particular emphasis on melanoma and laryngeal carcinoma development.

Clinical Case Description

An 80-year-old male patient presented to the dermatology department with two tumorous lesions located on left shoulder and the back. The lesion on the left shoulder was first noticed one-two years prior to the consultation by the patient's daughter.

The patient's medical history included laryngeal carcinoma, excised in 2025, staged pT1aN0M0, and arterial hypertension since 2016 for which he was on systemic therapy with nebivolol 5 mg once in the morning, telmisartan/hydrochlorothiazide 80 mg/12.5 mg once in the morning, and moxonidine once in the evening.

Dermatological examination revealed two distinct lesions: 1) a prominent, asymmetrically pigmented tumorous lesion located within the regio deltoidea sinistra (Figure 1). The lesion exhibits a heterogenous dark-brown color distribution and irregular, poorly defined borders. The lesion was highly suspected for cutaneous melanoma; and 2) a smaller, hyperpigmented lesion with irregular borders situated in the regio scapularis sinistra, clinically suspected for a dysplastic nevus (Figure 2).

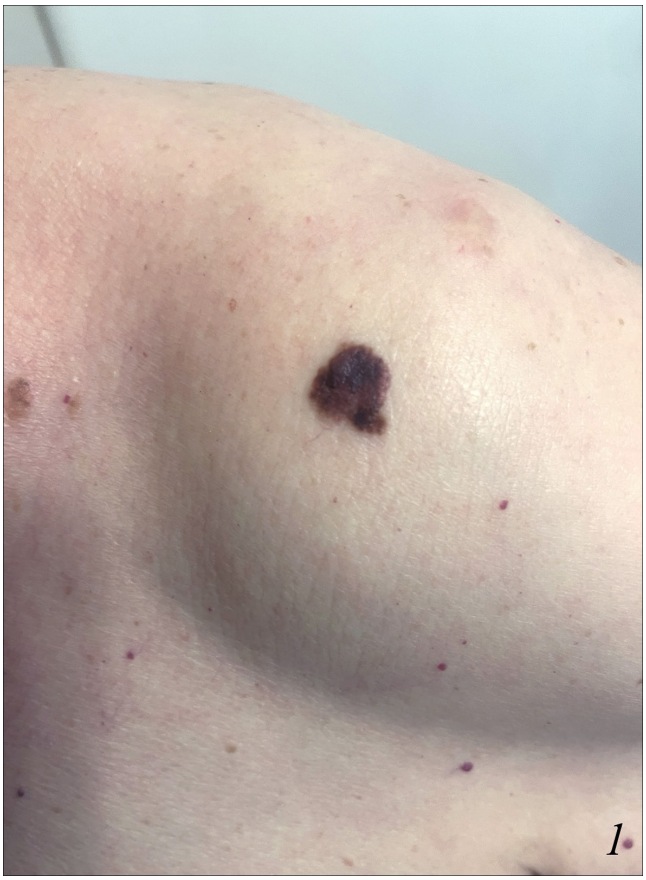

Figure 1. Dermatological examination: a prominent, asymmetrically pigmented tumorous lesion located within the regio deltoidea sinistra. The lesion exhibit a heterogenous dark-brown color distribution and irregular, poorly defined borders



Figure 2. Dermatological examination: a smaller, hyperpigmented lesion with irregular borders situated in regio scapularis sinistra

The patient was referred for surgical excision of both lesions.

Under local anesthesia with lidocaine, both lesions were excised with surgical safety margins of 0.3 mm in all directions (Figure 3). The wound edges were subsequently approximated using single interrupted sutures. The materials were sent for histopathological verification, which revealed: 1) superficial spreading malignant melanoma, Clark level II, Breslow thickness of 1 mm, without ulceration, low mitotic activity, a well-defined lymphocytic stromal reaction, clean resection lines; and 2) seborrheic keratosis.

For the melanoma, re-excision was recommended and subsequently performed with an additional surgical margin of 0.7 mm in all directions (Figure 4). The histopathological examination revealed no residual melanoma, all surgical margins were clear.

The serum S-100 protein and lactate dehydrogenase (LDH) levels were within normal limits. A whole-body contrast-enhanced computer tomography (CT) scan revealed no evidence of metastatic disease or other pathological abnormalities. Based on the clinical, histopathological, and imaging findings, the disease was staged as stage I T1NxMxR0.

Discussion

The role of nitric oxide and its interactions with reactive oxygen species is well-established in melanoma, breast and colon cancer [9]. Following systemic absorption and subsequent photodecomposition under UV radiation, nitrosamines may act as nitric oxide donors, which could be interpreted as their procarcinogenic effect [3, 9]. For example, two Japanese studies demonstrated that N-nitrosoproline and N-nitrosomorpholine may exert genotoxic effects following UV irradiation, prior to metabolic activation [10, 11].

N-nitrosamines are potent human carcinogens that may be formed either exogenously, during pharmaceutical manufacturing and/or storage processes, or endogenously from nitrosable drug precursors [12]. The presence of pre-existing N-nitrosamine impurities in pharmaceutical products is responsible for the global concern surrounding nitrosamine contamination [12]. Mutagenic N-nitroso derivatives may be generated from nitrosatable drug precursors – specifically, active pharmaceutical ingredients containing secondary and/or tertiary amine functional groups within their chemical structures – through nitrosation reactions following interaction with dietary nitrites under acidic gastric environment [12].



Figure 3. Status post stage I melanoma excision: The lesion is excised with surgical safety margins of 0.3 mm in all directions



Figure 4. Status post stage II melanoma excision: Re-excision is performed with an additional surgical margin of 0.7 mm in all directions

International studies have provided evidence that nitrosation products exhibit genotoxic properties and undergo enzymatic bioactivation, thereby inducing mutagenesis even at nano-level exposures [13]. Furthermore, the genotoxic activity of the resulting drug-nitrite interaction products has been demonstrated both in the presence and absence of metabolic activation [13]. Regulatory authorities, including European medicines Agency (EMA) [14] and the Food and Drug Administration (FDA) [15], have recognized nitroso derivatives resulting from drug-nitrite interactions as a significant safety concern, with the FDA classifying nitrosamine impurities according to their respective carcinogenic potency categories [15].

This carcinogenic potential is thought to be primarily associated with the metabolic activation of nitroso derivatives in the liver through alpha-hydroxylation, resulting in the formation of reactive carcinogenic metabolites and subsequent DNA damage [16, 17]. This mechanism has been implicated in the development of various solid and hematological malignancies, including gastrointestinal, urological, hematological, oropharyngeal, and neurological cancers [18-21].

Nitrosamine exposure/intake and drug-related nitroso formation have been associated in international studies with various malignancies, including brain tumors, neuroblastoma, and acute lymphoblastic leukemia [22], while exposure to nitrosamine-rich foods has also been associated with an increased risk of rectal cancer [23].

Currently, emerging data suggest an association between polypharmacy and the development of both cutaneous malignancies and solid tumors [24]. One proposed mechanism implicated in human carcinogenesis involves the exogenous/endogenous nitrosamine formation and their subsequent metabolic and photocarcinogenic pathways [25]. Following hepatic metabolic activation, nitrosamines may contribute to the development of solid tumors through the formation of reactive carcinogenic metabolites [25]. Alternatively, prior to hepatic metabolism, systemically absorbed nitrosamine compounds may undergo tissue distribution and subsequent cutaneous deposition, followed by photodecomposition upon UV radiation, potentially contributing to the development of skin cancer [25].

A distinction should be made between conventional photocarcinogenesis and nitroso-photocarcinogenesis, a mechanism in which polypharmacy, nitrosamine drug substance-related impurities (NDSRIs), and dietary exposure to nitrite-rich foods may represent important factors to the development of more rapid or potentially more aggressive types of tumors (Table 1).

Table 1. Key Clinical Differences between Standard Photocarcinogenesis and Nitroso-Photocarcinogenesis

Attribute	Standard Photocarcinogenesis	Nitroso-Photocarcinogenesis
Primary Driver	Direct UV DNA damage (e.g., thymine dimers)	UV interaction with chemical contaminants
Systemic Factors	Sun exposure, skin phenotype (melanin levels)	Polypharmacy, NDSRIs, nitrite diet
Clinical Presentation	Solitary or gradual skin lesions over decades	Rapid, multiple, or aggressive presentation of tumors

Acronyms: NDSRIs – nitrosamine drug substance-related impurities; UV – ultraviolet

Associations between cutaneous and internal malignancies have been reported even before the concept of exogenous/endogenous nitrosation was proposed, including the coexistence of cutaneous melanoma, colorectal carcinoma and Kaposi sarcoma [26], choroidal melanoma and colorectal carcinoma [27], and cutaneous melanoma and prostate carcinoma [28].

Although a direct association between upper aerodigestive tract cancers and antihypertensive medication use has not been firmly established, studies have identified hypertension itself as a potential risk factor for oral, laryngeal and esophageal cancers [30]. The reported hazard ratios (HR) were 1.11 (95% CI 1.04-1.17) for oral cancer; 1.23 (95% CI 1.13-1.33) for laryngeal cancer; and 1.25 (95% CI 1.18-1.33) for esophageal cancer, after adjustment for age and other potential variables including gender, smoking status, alcohol intake, exercise, body mass index, and diabetes [29].

Patients with untreated hypertension were reported to have the highest risk of developing oral cancer (HR 1.15; 95% CI 1.05-1.26), laryngeal cancer (HR 1.25; 95% CI 1.09-1.44), and esophageal cancer (HR 1.47; 95% CI 1.33-1.63) after adjusting [29]. Thus, hypertension was associated with an increased risk of oral, laryngeal, and esophageal cancers, despite the absence of detailed biochemical information, including characterization of the respective cancer cell types [29]. Whether these associations are attributable to the underlying pathophysiological mechanisms of hypertension, to the medications used for its treatment, or to a combination of both, remains uncertain.

Nevertheless, such clinicopathological observations are of potential relevance, as noted in our patient, who developed laryngeal carcinoma several years after initiating antihypertensive therapy.

Antihypertensive medications have long been associated with cutaneous deposition and accumulation, potentially capable of inducing phototoxic reactions [30-33].

Nebivolol, a beta-blocker, contains a central secondary amine functional group within its chemical structure [34], rendering it structurally susceptible to nitrosation by nitrosating agents, such as environmental nitrites under acidic or during specific manufacturing processes [28]. This may result in the formation of N-nitroso-nebivolol, which is classified within the FDA's carcinogenic potency category 4 with a recommended acceptable intake (AI) limit of 1500 ng/day [16].

A 2025 analysis of melanoma outcomes in patients receiving beta-blockers incorporated data from 12 additional studies involving 21,582 patients and demonstrated an association between beta-blocker use and improved disease-free survival, while no significant association was observed with either melanoma-specific or overall survival [35].

Another study published in the European Journal of Cancer analyzed more than 200,000 patients with melanoma who initiated beta-blocker therapy only after melanoma diagnosis [36]. The results likewise demonstrated no statistically significant effect of beta-blocker exposure on overall survival, regardless of the timing, duration, or dosage of beta-blocker use [36].

Beta-blocker use, nebivolol for example, in combination with other potentially or confirmed nitrosamine-contaminated medications has been described as a potential risk factor for the simultaneous development of multiple cutaneous melanomas and dysplastic nevi [37, 38]. The common link among these pharmacologically heterogeneous classes of medications may be phototoxicity [39]. Notably, photolability and phototoxicity have been recognized for decades as nonspecific properties of nitrosamines, regardless of their established carcinogenic potential [40].

Nitroso-contamination or formation – including N-nitrosodiethylamine (NDEA) and N-nitrosodimethylamine (NDMA), may occur exogenously during pharmaceutical synthesis or arise de novo under certain conditions in drugs containing secondary or tertiary amines [41].

Telmisartan does not contain a secondary amine functional group in its final molecular structure; rather, it contains tertiary amines, aromatic amines and a carboxylic acid group [42]. However, it may undergo demethylation to from N-desmethyl telmisartan, a degradation product that introduces a secondary amine site capable of reacting with environmental nitrites and subsequently forming a nitroso derivative of telmisartan [43, 44].

In the literature, telmisartan has already been described as a potential inductor for melanoma development [45, 46], with international studies suggesting that angiotensin receptor blockers (sartans), may promote carcinogenesis in the direction of melanoma development and metastatic progression [47, 48].

Hydrochlorothiazide, another widely used antihypertensive agent, contains a secondary amine group within its heterocyclic ring core [49], which represents a susceptible site for nitrosation. This may result in the formation of N-nitroso-hydrochlorothiazide, a nitroso compound included in the FDA's list of nitrosamine impurities and classified within carcinogenic potency category 4, with a recommended acceptable intake (AI) limit of 1500 ng/day [15].

International studies have demonstrated an association between high cumulative exposure to hydrochlorothiazide use (≥ 5,000 defined daily dose; ≥ 125,000 mg) and an increased risk of any skin cancer (adjusted hazard ratio 5.32; 95% confidence interval (95% CI), 2.40-11.81), keratinocyte carcinoma (adjusted hazard ratio 7.31, 95% CI 3.12-17.13), basal cell carcinoma (adjusted hazard ratio 7.72, 95% CI 3.11-19.16) and squamous cell carcinoma (adjusted hazard ratio 19.63, 95% CI 3.12-123.56) [50].

A study by Jensen et al. (2008) [51] reported an increased risk of squamous cell carcinoma (incidence rate ratio (IRR), 1.79; 95% confidence interval (CI): 1.45-2.21)) and malignant melanoma (IRR of 1.43 (95% CI: 1.09-1.88)) among patients receiving combined amiloride and hydrochlorothiazide therapy. An increased risk of malignant melanoma (IRR of 3.30 (95% CI: 1.34-8.10)) was observed among users of indapamide [51].

Another confirmatory study by Shao et al. (2022) [52] found that hydrochlorothiazide use was associated with an increased risk of several melanoma subtypes, including superficial spreading melanoma (OR 1.18, 95% CI 1.05-1.33), nodular melanoma (OR 1.23, 95% CI 1.08-1.39), and lentigo maligna melanoma (OR 1.33, 95% CI 1.08-1.65). Furthermore, increasing cumulative doses of hydrochlorothiazide were associated with higher odds for melanoma [52].

Telmisartan/hydrochlorothiazide is a commonly used combination for antihypertensive therapy, and

several studies have associated its use with an increased risk of skin cancer, particularly melanoma [53].

Moxonidine contains a secondary amine functional group linking its pyrimidine and imidazoline rings, representing a potential site for nitrosamine formation under specific manufacturing or storage conditions, as well as under acidic gastric conditions [12]. This may result in the formation of N-nitroso-moxonidine [54]. Moxonidine may undergo systemic distribution beyond the blood circulation, with a proportion reaching peripheral compartments such as the skin prior to hepatic metabolism, rather than remaining in the plasma [55, 56]. Moxonidine in the context of polymedication has been reported in association with the development of melanoma and dysplastic nevi [57].

Conclusions

Polymedication regimes have become increasingly prevalent in modern societies, particularly in the context of the growing burden of multimorbidity and obesity. In an era of extensive polypharmacy use, the cumulative and potentially interacting adverse effects of multiple medications may have significant clinical consequences. The increasing incidence of human cancer observed in recent decades raises the possibility that polypharmacy, through concurrent pharmacological interactions, may enhance the effects of certain drugs or their nitroso derivatives, potentially increasing the risk of human carcinogenesis. The emerging concept of drug-related nitrosogenesis, encompassing both the cutaneous carcinogenesis and solid tumorigenesis, may provide a potential explanation for the increasing cancer incidence observed in the modern era.

In this context, we present another case of cutaneous melanoma and laryngeal carcinoma occurring following long-term systemic therapy with nebivolol, telmisartan/hydrochlorothiazide, and moxonidine.

Conflicts of Interest Statement: *The authors declare no conflict of interest.*

Ethical Statement: *Ethics approval statement is not required.*

Informed Consent Statement: *Written informed consent for publication of their details was obtained from the patient.*

References

1. Bamford CH. A study of the photolysis of organic nitrogen compounds. Part I. Dimethyl- and diethyl-nitrosoamines. J Chem Soc, 1939, 12-17.
2. Beard JC, Swager TM. An organic chemist's guide to N-nitrosamines: their structure, reactivity, and role as contaminants. J Org Chem, 2021, 86(3):2037-2057.
3. Tchernev G, Tchernev KG Jr, Broshtilova V. Investigating novel etiologies of skin cancer. the correlation between nitrosamines in pharmaceuticals and photocarcinogenesis: the ROS-nitric oxide interplay/procarcinogenic action (during polymedication intake) as skin cancer triggering factor. Eur J Med Health Res, 2025, 3(6):4-10.
4. Tchernev G, Tchernev KG Jr, Broshtilova V, et al. Generic drug structure (secondary/tertiary amino groups) within the polypharmacy as main risk factors for skin related (nitroso) photocarcinogenicity but also for a solid human cancer: investigative report with focus on cutaneous melanoma and prostate carcinoma. Eur J Med Health Res, 2026, 4(4):137-45.
5. Grigoruta M, Li L, Chen L, et al. S-nitrosylation of p53 in melanoma cells under nitrosative stress. Int J Mol Sci, 2025, 26(13):6512
6. Kordeva S, Tchernev KG Jr, Broshtilova V, et al. Environmental carcinogenesis: nitric oxide release after photodecomposition of nitrosocontaminants in drugs (under UV exposure) as substantial factor for skin carcinogenicity. sertraline induced cutaneous melanoma – third reported case in scientific literature. Eur J Med Health Res, 2025, 3(6):128-35.
7. Nardone B, Majewski S, Kim AS, et al. Melanoma and non-melanoma skin cancer associated with angiotensin-converting-enzyme inhibitors, angiotensin-receptor blockers and thiazides: a matched cohort study. Drug Saf, 2017, 40(3):249-255.
8. Tchernev G, Tchernev KG Jr, Kordeva S. Secondary/tertiary amines in generic drug structure in the context of polypharmacy as main source for photocarcinogenicity in humans and subsequent melanoma development and progression: spotlight on two new cases. Eur J Med Health Res, 2026, 4(4):28-42.
9. Monteiro HP, Rodrigues EG, Amorim Reis AKC, et al. Nitric oxide and interactions with reactive oxygen species in the development of melanoma, breast, and colon cancer: a redox signaling perspective. Nitric Oxide, 2019, 89:1-13.
10. Tomozane N, Tanaka N, Arimoto-Kobayashi S. Photogenotoxicity of N-nitrosoproline plus simultaneous UVA irradiation in human-derived keratinocytes. Mutat Res Genet Toxicol Environ Mutagen, 2025, 905:503876.
11. Mochizuki H, Nagazawa Y, Arimoto-Kobayashi S. Genotoxicity and the stability of N-nitrosomorpholine activity following UVA irradiation. Mutat Res Genet Toxicol Environ Mutagen, 2024, 893:503721.
12. Regulska K, Kolenda T, Michalak M, et al. Impact of ramipril nitroso-metabolites on cancer incidence – in silico and in vitro safety evaluation. Rep Pract Oncol Radiother, 2023, 28(5):612-622.
13. Ozhan G, Alpertunga B. Genotoxic activities of drug-nitrite interaction products. Drug Chem Toxicol, 2003, 26(4):295-308.
14. European Medicines Agency. Nitrosamine impurities. European Medicines Agency. Science Medicines Health. Accessed June 01, 2026, https://www.ema.europa.eu/en/human-regulatory-overview/post-authorisation/referral-procedures-human-medicines/nitrosamine-impurities
15. FDA. US Food and Drug Administration. CDER Nitrosamine Impurity Acceptable Intake Limits. FDA. US Food and Drug Administration. Accessed June 11, 2026, https://www.fda.gov/regulatory-information/search-fda-guidance-documents/cder-nitrosamine-impurity-acceptable-intake-limits

16. Loeppky RN, Li YE. Nitrosamine activation and detoxication through free radicals and their derived cations. IARC Sci Publ, 1991, (105):375-82.
17. Yamazaki H, Inui Y, Yun CH, et al. Cytochrome P450 2E1 and 2A6 enzymes as major catalysts for metabolic activation of N-nitrosodialkylamines and tobacco-related nitrosamines in human liver microsomes. Carcinogenesis, 1992, 13(10):1789-94. doi: 10.1093/carcin/13.10.1789.
18. Seyyedsalehi MS, Mohebbi E, Tourang F, et alK. Association of dietary nitrate, nitrite, and N-nitroso compounds intake and gastrointestinal cancers: a systematic review and meta-analysis. Toxics, 2023, 11(2):190.
19. Zupančič D, Romih R. Urinary bladder cancer induced by N-Butyl-N-(4-hydroxybutyl)-nitrosamine. Methods Mol Biol, 2024, 2773:25-32.
20. Preston-Martin S, Yu MC, Benton B, et al. N-nitroso compounds and childhood brain tumors: a case-control study. Cancer Res, 1982, 42(12):5240-5.
21. National Toxicology Program. 15th Report on carcinogens [Internet]. Research Triangle Park (NC): National Toxicology Program; 2021 Dec 21. N-Nitrosamines: 15 Listings. Available from: https://www.ncbi.nlm.nih.gov/books/NBK590783/
22. Sirirungreung A, Hansen J, He D, et al. Exposure to nitrosatable drugs during pregnancy and childhood cancer: a matched case-control study in Denmark, 1996-2016. Pharmacoepidemiol Drug Saf, 2023, 32:496-505.
23. Loh YH, Jakszyn P, Luben RN, et al. N-nitroso compounds and cancer incidence: the European Prospective Investigation into Cancer and Nutrition (EPIC)-Norfolk Study. Am J Clin Nutr, 2011, 93:1053-1061
24. Tchernev G, Oliveira N, Kandathil LJ, et al. Telmisartan (and/or nitrosamine) induced prostate carcinoma and atypical fibroxanthoma: first report in world literature. Med Review, 2022, 58(1):65-67.
25. Tchernev G, Tchernev Jr KG, Kordeva S. Secondary/tertiary amines in the generic polymedication as milestone for drug/food-related nitroso formation and subsequent photocarcinogenicity/skin cancer development in humans: advancement/rotation flaps as treatment choice. Eur J Med Health Res, 2026, 4(3):215-228.
26. Tchernev G, Poterov G. Drug induced cancers: simultaneously development of cutaneous melanoma, colon carcinoma and Kaposi sarcoma under valsartan/hydrochlorothiazide. Clin Res Dermatol Open Access, 2020, 7(5):1-8.
27. Tchernev G, Poterov G. Antihypertensive drugs and cancer: simultaneously development of choroidal melanoma and colon carcinoma after administration with valsartan/hydrochlorothiazide. Clin Res Dermatol Open Access, 7(4):1-4.
28. Tchernev G, Tchernev Jr KG, Broshtilova V, et al. Generic drug structure (secondary/tertiary amino groups) within the polypharmacy as main risk factors for skin related (nitroso) photocarcinogenicity but also for a solid human cancer: investigative report with focus on cutaneous melanoma and prostate Ca. Eur J Med Health Res, 2026, 4(4): 137–145.
29. Seo JH, Kim YD, Park CS, et al. Hypertension is associated with oral, laryngeal, and esophageal cancer: a nationwide population-based study. Sci Rep, 2020, 10(1):10291.
30. Lozzi F, Di Raimondo C, Lanna C, et al. Latest evidence regarding the effects of photosensitive drugs on the skin: pathogenetic mechanisms and clinical manifestations. Pharmaceutics, 2020, 12(11):1104.
31. George EA, Baranwal N, Kang JH, et al. Photosensitizing medications and skin cancer: a comprehensive review. Cancers (Basel), 2021, 13(10):2344.
32. Karkoszka M, Rok J, Rzepka Z, et al. Phototoxic reactions inducted by hydrochlorothiazide and furosemide in normal skin cells – in vitro studies on melanocytes and fibroblasts. Int J Mol Sci, 2024, 25(3):1432.
33. Tchernev G, Kordeva S. Melanoma in situ and phototoxic drug reaction appearing simultaneously after antihypertensives intake: photo nitroso carcinogenicity of drugs as possible risk factor for the development and progression of cutaneous melanoma. Acta Medica Bulgarica, 2025, 52(4): 79-83.
34. NIH. National Library of Medicine. National Center for Biotechnology Information. PubChem Compound Summary for CID 71301, Nebivolol. NIH. National Library of Medicine. National Center for Biotechnology Information. Accessed August 30, 2026, https://pubchem.ncbi.nlm.nih.gov/ compound/Nebivolol.
35. Muller NM, Tan SX, Vipulaguna N, et al. Beta-blockers and cutaneous melanoma outcomes: a systematic review and random-effects meta-analysis. Pigment Cell Melanoma Res, 2025, 38(1):e13225.
36. Livingstone E, Hollestein LM, van Herk-Sukel MP, et al. β-Blocker use and all-cause mortality of melanoma patients: results from a population-based Dutch cohort study. Eur J Cancer, 2013, 49(18):3863-71.
37. Tchernev G. Nitrosogenesis of cutaneous melanoma: simultaneously development of primary cutaneous thick melanoma of the breast, thin melanoma/dysplastic mole of the back during parallel intake of bisoprolol, amlodipine and valsartan/HCT: nitrosamine polycontamination in the multimedication as the most powerful skin cancer trigger. Georgian Med News, 2023, (339):83-88.
38. Tchernev G, Broshtilova V, Tchernev Jr KG, et al. Giant pedunculated mushroom-like cutaneous melanoma during systemic administration with nebivolol – phototoxicity and photocarcinogenicity mediated through the nitroso contamination in pharmaceuticals as possible new pathogenetic explanation. Medical Review, 2026, 62(1), 57-62.
39. Davis AE, Kennelley GE, Amaye-Obu T, et al. The phenomenon of phototoxicity and long-term risks of commonly prescribed and structurally diverse drugs. J Photochem Photobiol, 2024, 19:100221.
40. Nishie K, Norred WP, Wasserman A, et al. Phototoxicity and differential hepatotoxicity as biological indicators of nitrosamine activity. Toxicol Appl Pharmacol, 1972, 23(4):680-91.
41. FDA. US Food and Drug Administration. Laboratory analysis of valsartan products. FDA. US Food and Drug Administration. Accessed June 10, 2026, https://www.fda.gov/drugs/drug-safety-and-availability/laboratory-analysis-valsartan-products
42. Schumacher TJ, Gardner ZS, McParlan MP, et al. Synthesis and Biological Evaluation of Telmisartan Alkylamine Derivates as Potential Anticancer Agents. Anticancer Res, 2024, 44 (3):911-919.
43. Kumar AS, Ghosh S, Mehta GN. Efficient and improved synthesis of Telmisartan. Beilstein J Org Chem, 2010, 6:25.
44. Chemicea. N-nitroso N-desmethyl Telmisartan. Chemicea. Accessed June 10, 2026, https://chemicea.com/product/n-nitroso-n-desmethyl-telmisartan
45. Tchernev G, Bitolska A, Patterson JW. Telmisartan (and/or nitrosamine) – induced occult melanoma: first reported case in world literature. Expert Rev Clin Pharmacol, 2021, 14(9):1075-1080.
46. Tchernev G, Poterov G, Malev V. Sartans and melanoma: valsartan induced multiple primary cutaneous melanomas: first

description in the medical literature!. Clin Res Dermatol Open Access, 2020, 7(4):1-3.
47. Liu LH, Fan X, Li HT, et al. Angiotensin II promotes melanogenesis via angiotensin II type 1 receptors in human melanocytes. Mol Med Rep, 2015, 12(1):651-656.
48. Sable K, Majewski S, Nardone B, et al. Association of melanoma and nonmelanoma skin cancer with antihypertensive drugs: a report from the research on adverse drug events and reports project. Poster 3167. J Am Acad Dermatol, 2016, 74(5, supplement 1):AB221.
49. U.S. Food and Drug Administration. Hydrochlorothiazide. PrecisionFDA. Accessed June 10, 2026, https://precision.fda.gov/ginas/app/ui/substances/30c841c3-7422-44ca-948a-9bfbe9f0d977
50. Haisma MS, Greven N, Logendran M, et al. Chronic use of hydrochlorothiazide and risk of skin cancer in Caucasian adults: a PharmLines initiative inception cohort study. Acta Derm Venereol, 2023, 103:adv3933.
51. Jensen AØ, Thomsen HF, Engebjerg MC, et al. Use of photosensitising diuretics and risk of skin cancer: a population-based case-control study. Br J Cancer, 2008, 99(9):1522-8.
52. Shao SC, Lai CC, Chen YH, et al. Associations of thiazide use with skin cancers: a systematic review and meta-analysis. BMC Med, 2022, 20(1):228.
53. Tchernev G, Patterson JW. Telmisartan/hydrochlorothiazide-induced nevus-associated cutaneous melanoma: first report in the medical literature. Expert Rev Clin Pharmacol, 2021, 14(3):289-293.
54. Veeprho. N-nitroso moxonidine-A. Veeprho. Accessed June 10, 2026, https://veeprho.com/impurities/n-nitroso-moxonidine-a/
55. EMC. Moxonidine 400 microgram film-coated tablets. EMC. Electronic medicines compendium. Accessed June 10, 2026, https://www.medicines.org.uk/emc/product/4138/smpc#gref
56. Li J, Zeng S, Zhang E, et al. Spatial metabolomics to discover hypertrophic scar relevant metabolic alterations and potential therapeutic strategies: a preliminary study. Bioorg Chem, 2024, 153:107873.
57. Tchernev G, Naydekova N. Melanoma and dysplastic nevi development after ranitidine/rilmenidine/моxonidine, lercanidipine, rosuvastatin and verapamil/trandolapril – new data/case series. The potential role of nitrosamine/NDSRIs contamination in polymedication as substantial skin cancer triggering factor. Georgian Med News, 2023, (344):152-158.

Received: June 31th 2026.